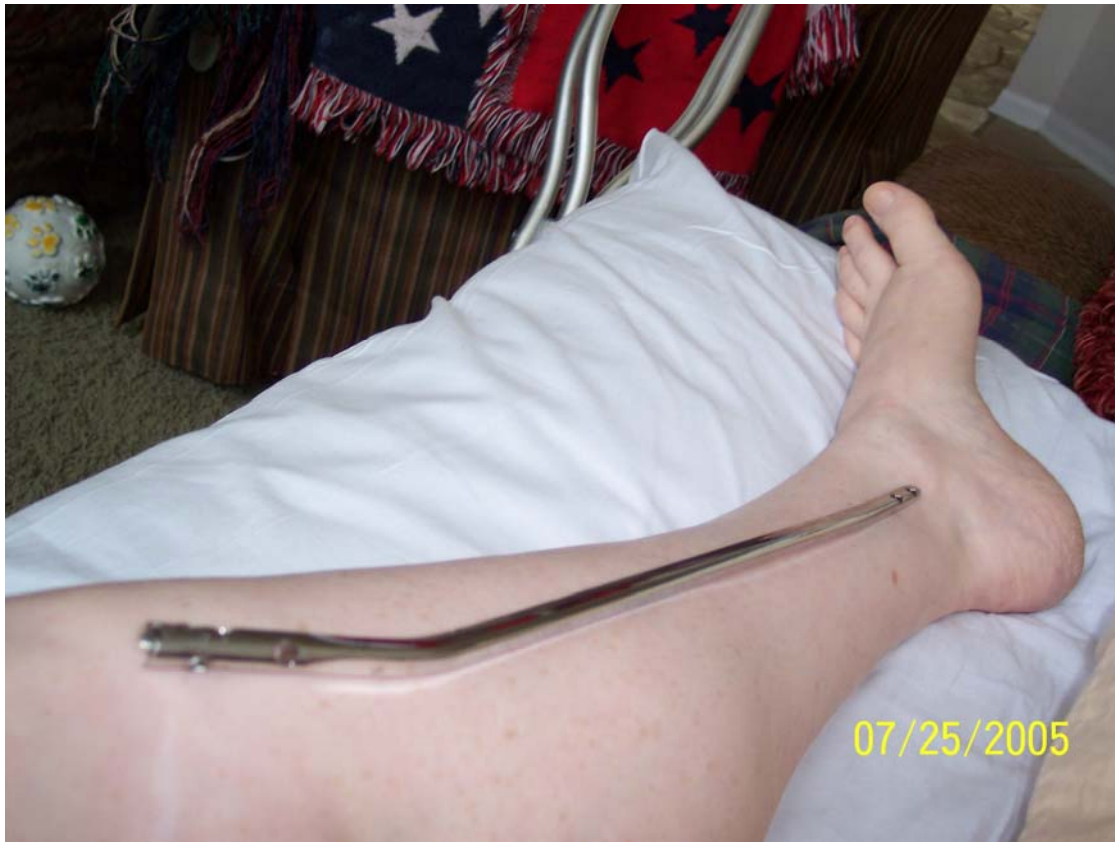
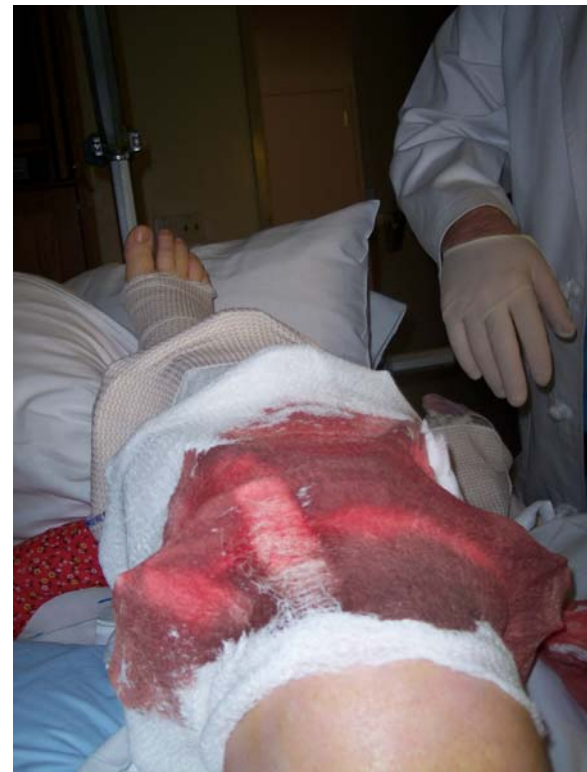
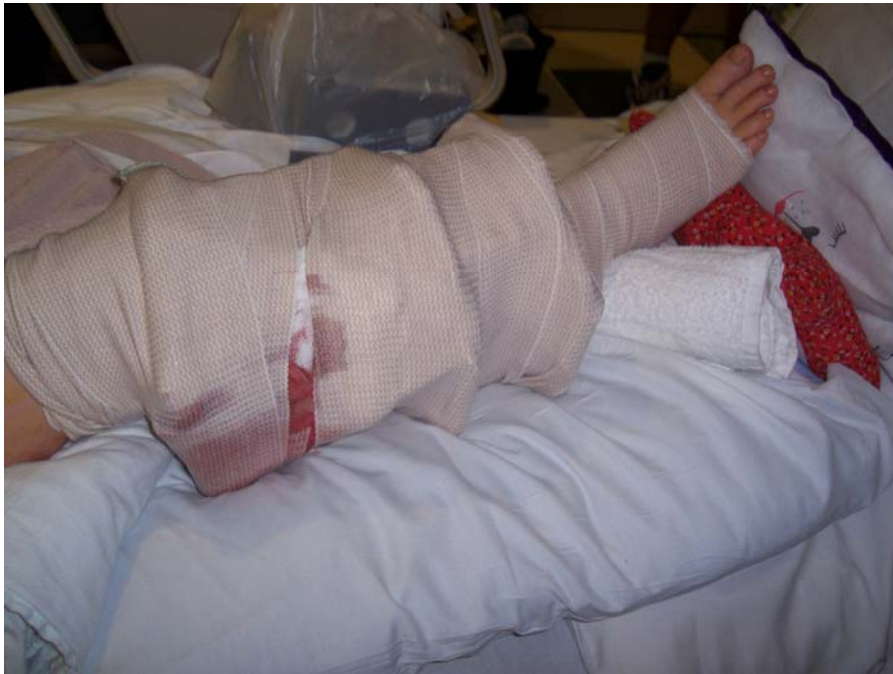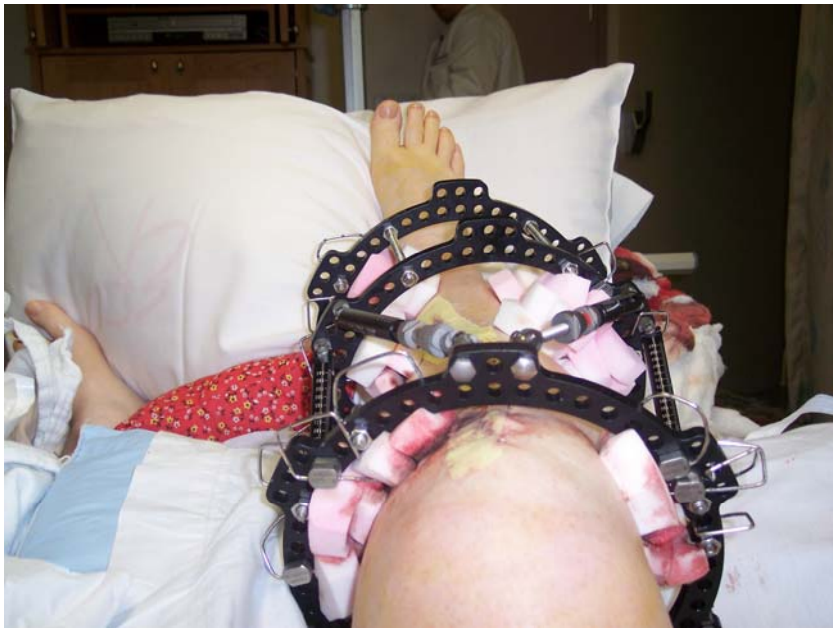Surgery, July 19th and hospital
stay through July 23rd.



- It took four hours to get this rod out of my right leg. Here it is laying against my left leg so you can see the size of it. He had to split my tibia from knee to ankle with a chisel to open up the tibia enough to get it out. What is amazing though is he did most of it under the skin so the incisions are not as bad as you'd think. You can see the scrape line of the chisel in this rod – what you still cannot see here is that the rod is triangular. It took another 1 ½ to do the “osteotomy” which is where he cuts my bone all the way through right under my knee, puts in pins and then positions the external fixator.

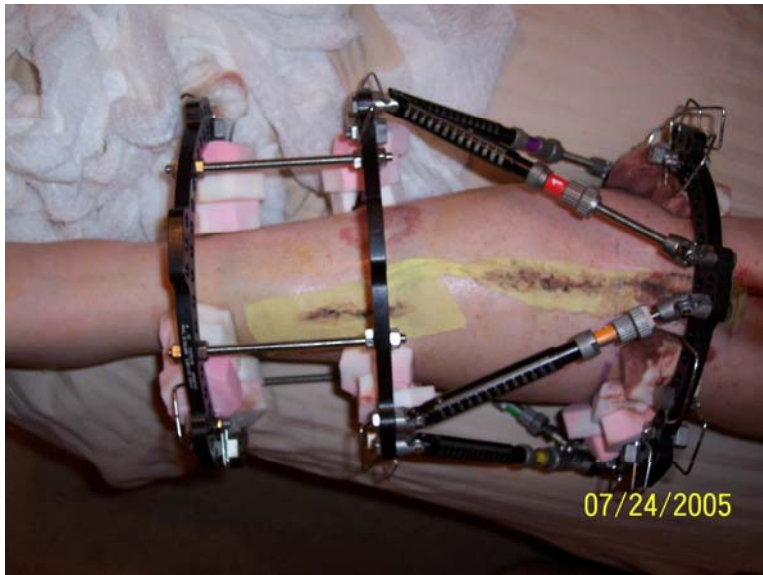- This is me the night after my surgery. My leg was so wrapped I had no idea what it looked like under these bandages so the next day when he changed my bandages, I was surprised to learn how much blood I had lost.



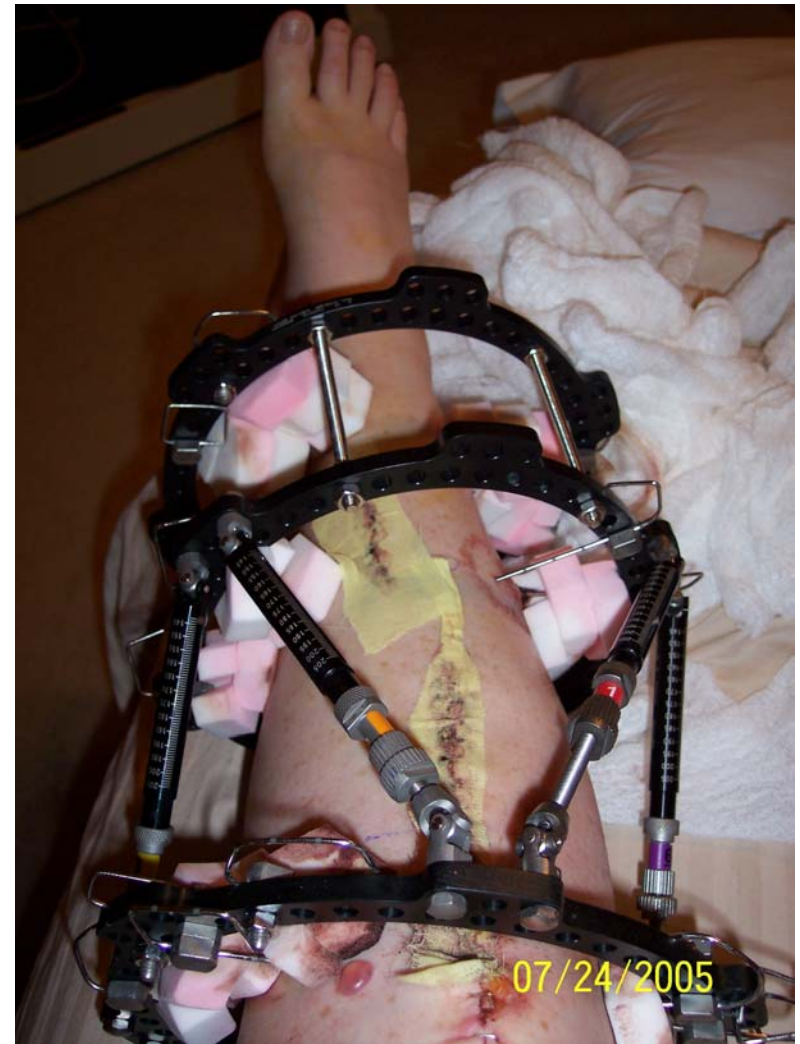
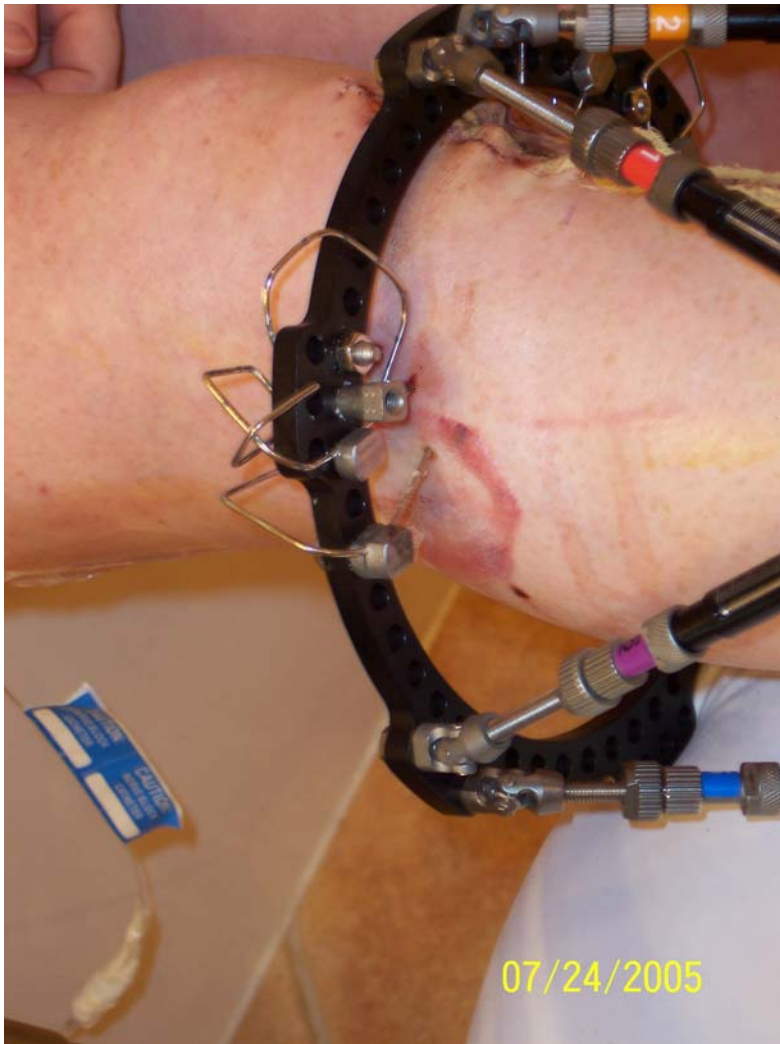
- This is the external fixator. The sponges go around my pins until they stop bleeding. There are 16 pins total.

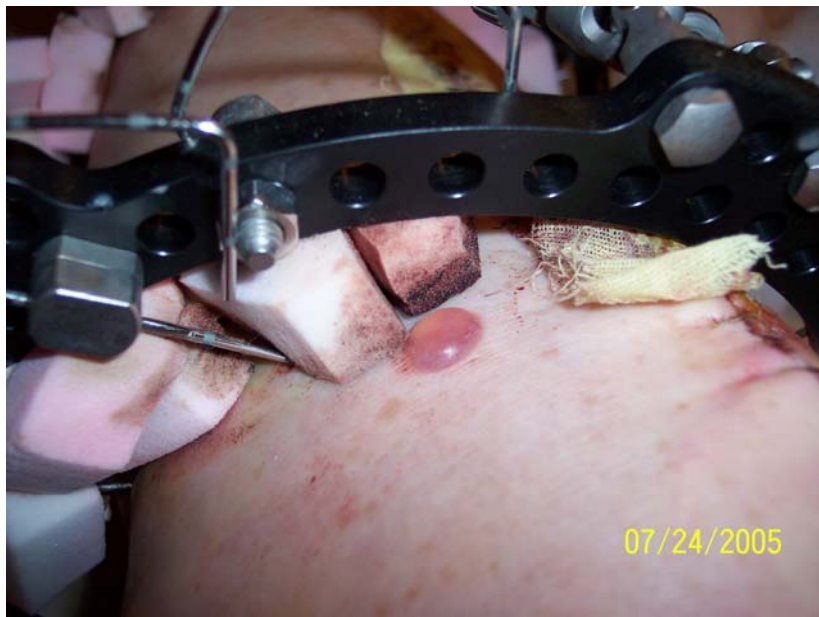
- You can see how crooked my leg is on the bottom photo...21 degrees off. This is a TOP view of my leg. Again this is looking down on the top of my shin.



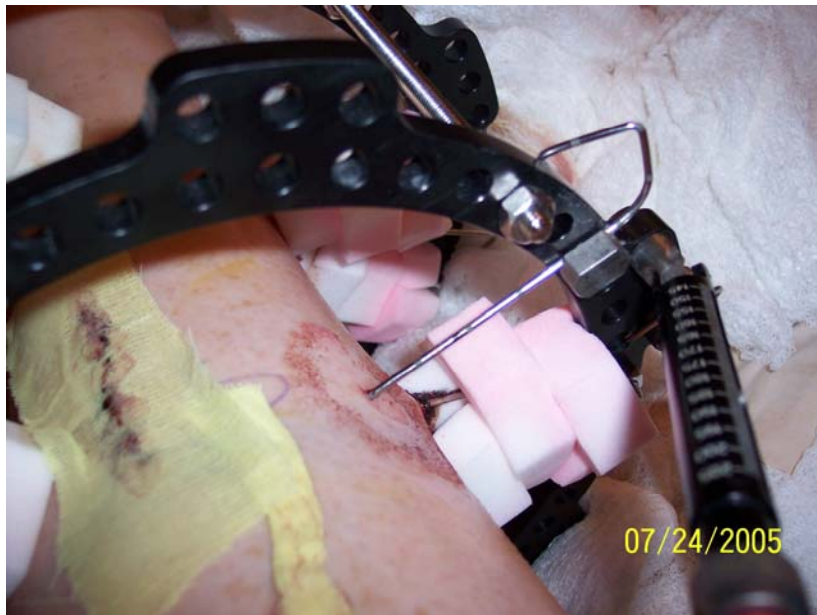- The bottom rung is only on there because my tibia was split – not to reposition the leg. You can see that the bottom rungs position is fixed. The upper two rungs have the diagonal tension rods...it is their job to separate my bone enough to form an “open space wedge” where he cut through the tibia. All of this, of course, to straighten it.

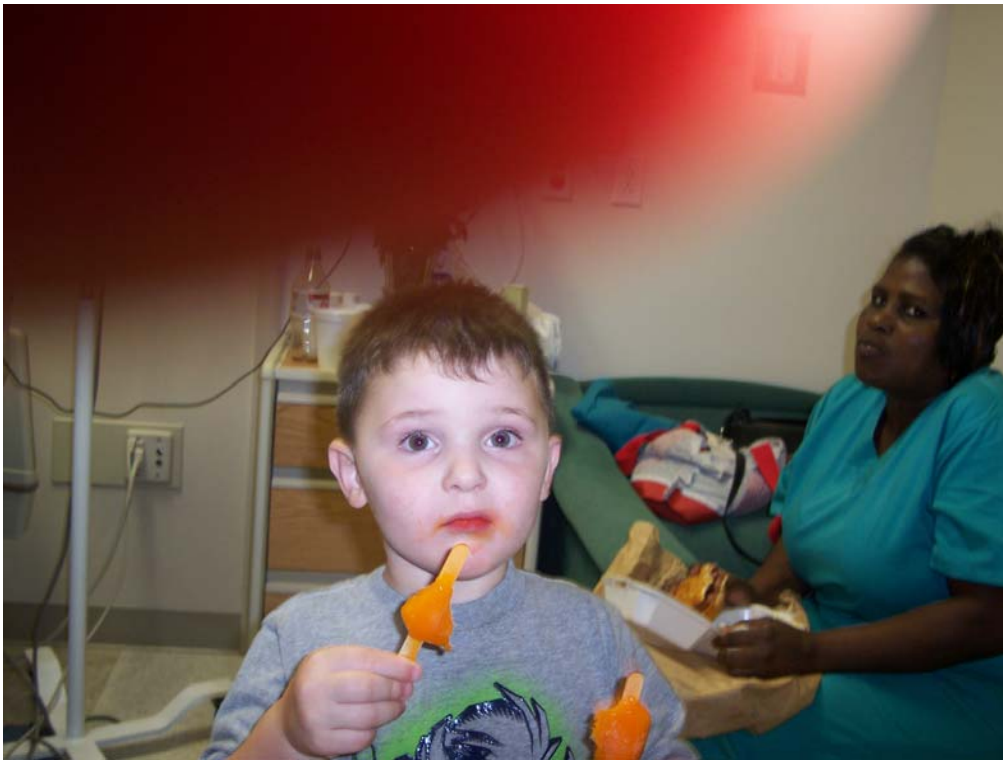

- For some reason, I have blisters all over my leg. The red circle in the pix on the left is a giant blister and the gum drop size one by my knee in the photo on the right is an another. I think I have about nine of them.



- These thick wires are what they call “pins”. They run all the way through my leg to the other side of the fixator. Inside my skin there are “stoppers” to keep the bone from sliding along the pin. I have eight on the top rung, four on the middle and four on the bottom.





- Here is just one of my visitors to the hospital, Landon at 27 mos. Foster took all the pictures (see his finger?) so there is not one single one of him!