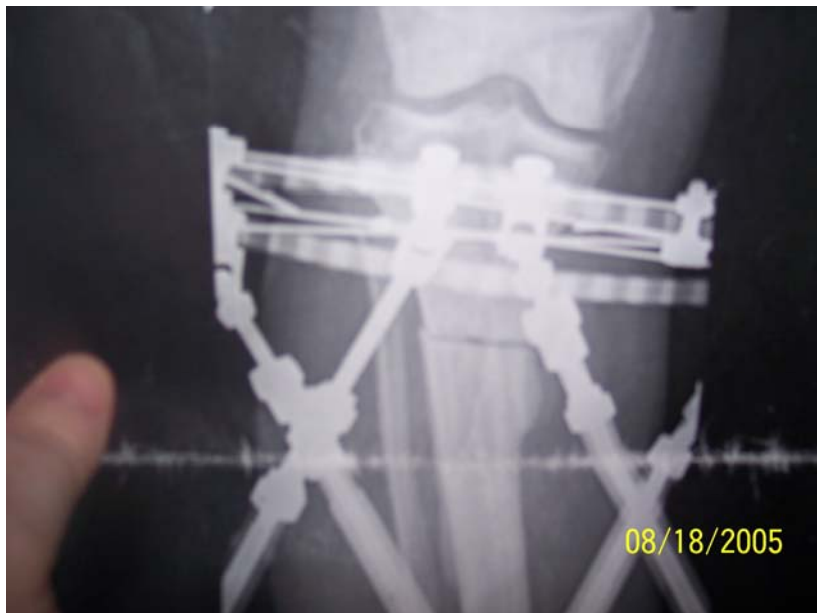

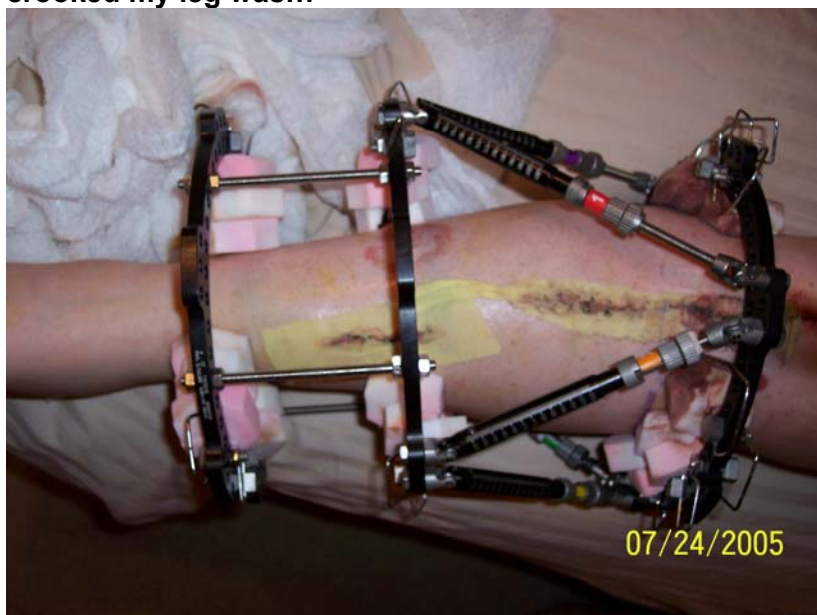UPDATE ON MY LEG:

Over the last four weeks from 21 degrees crooked to STRAIGHT!! Now we have to determine if it needs to be lengthened but the angle is finally correct. You cannot see where the bone chiseled in these x-rays because they are straight down from the top.

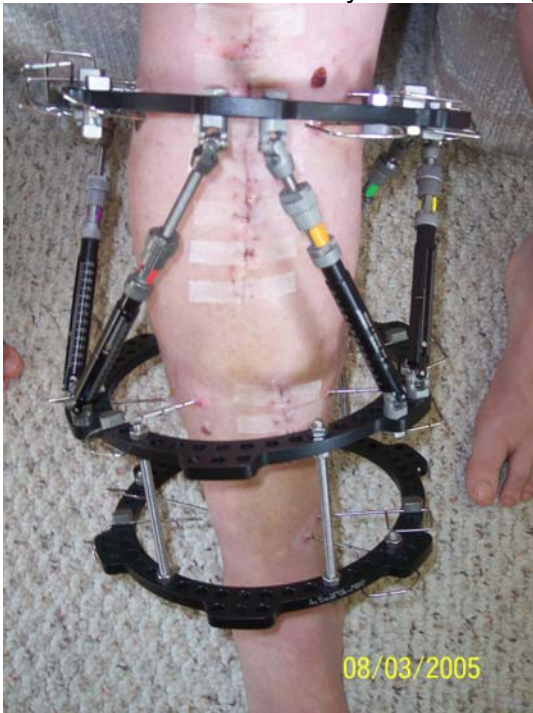
Here is my xray taken on July 29th (*the picture of the xray was taken on Aug 18th*). You see there is only the directly horizontal cut in my bone – it's not separated at all. You will see later how this is opened up.



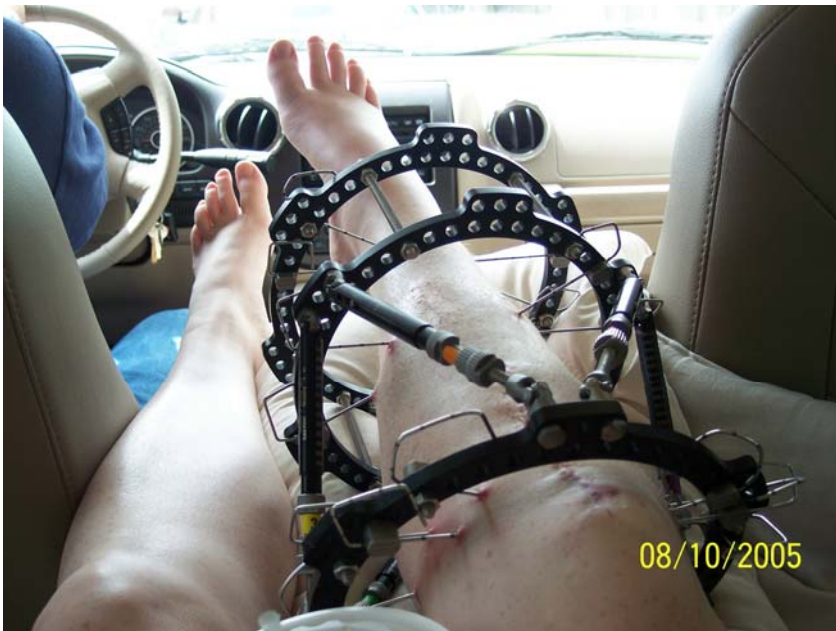These were taken in the hospital right after my surgery. This is a TOP view – **yes, a TOP view of my leg** - the last day I was in the hospital. That yellow swatch on the right is directly under my KNEE and the other one is directly on top of my shin. You are looking directly down on the front of my shin. **That's how crooked my leg was...**



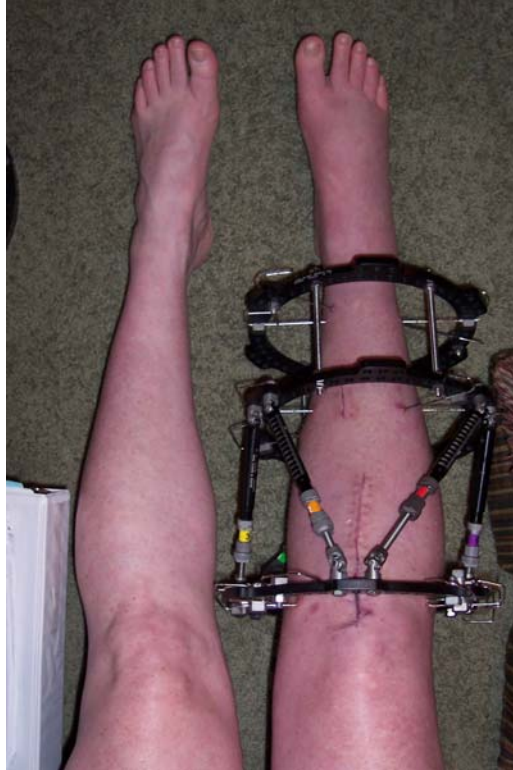
This was taken about 5 days after starting movement of my bone - taken on Aug 3 - not much difference yet.



This was one week later, on August the 10th, about 12 days into the straightening process:

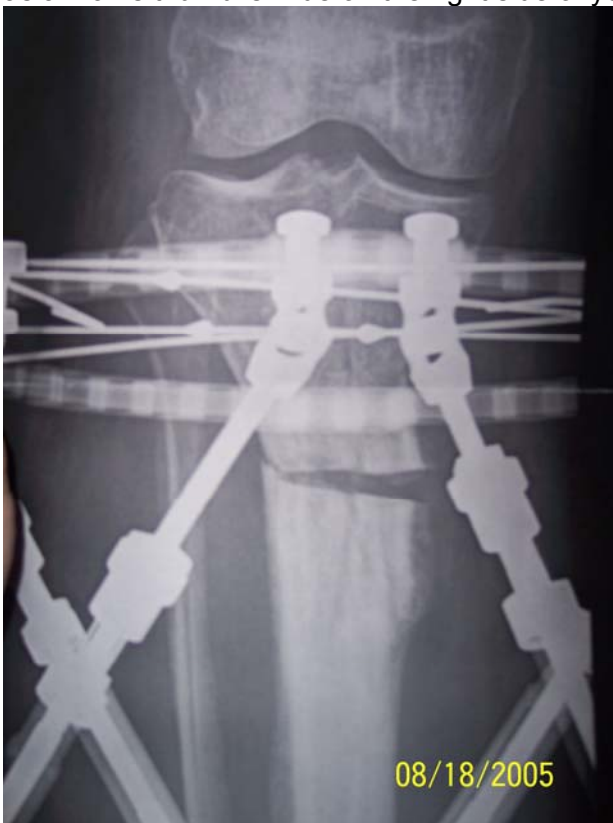

This was taken on August the 16th, the last day of the the straightening process. I have to have final x-rays taken but the doctor thinks it is straight at this point. He said, “your x-ray’s are friggin’ great!” I think “friggin’ from a doctor is pretty good, don’t you? ☺ YAY. Now I have to wait three days to start trying to bear weight on this leg. After about two weeks of semi weight bearing, we will evaluate if/how much the leg has to be lengthened. If it does, then the process is much the same as I’ve just endured with the straightening. If I

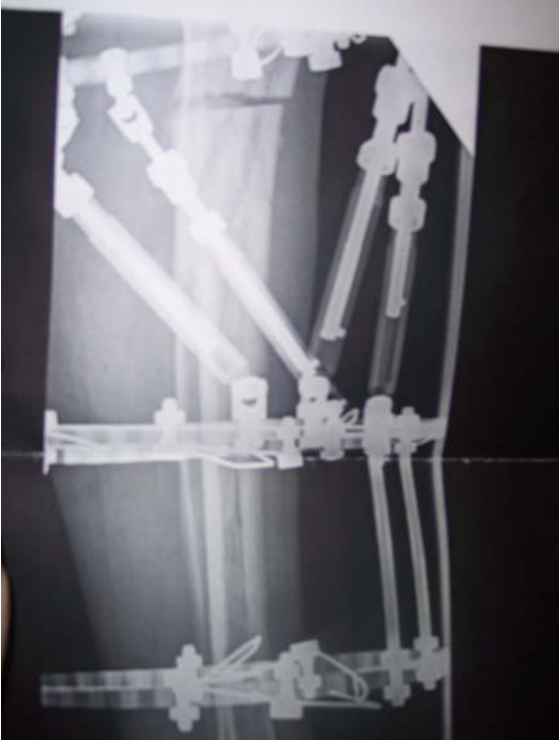

don’t, then I’m two weeks into my recovery.

Here’s the x-ray now...taken August 10th. See the difference in the “osteotomy”? It’s open up about as big as a man’s thumb is wide on the right side of your screen...this is what straightened the leg.



A last thought to show you....this one was taken about Aug 10th so not quite through the process but at least you can see where the tension is put on my bone to move it. The "pins" aka rods through my bones are being hidden by the metal rings of the external fixator here but you get the idea. You can see where he chiseled my bone from knee to ankle here...itt's the grey line all the way



down.